

Hyalofast[®]

One-step Cartilage Repair
Product Brochure



Hyalofast: The Simple, Adaptable and Proven Cartilage Repair Solution

Hyalofast is a one-step cartilage repair product made from a 3D non-woven scaffold composed of Hyaff which is a 100% benzyl ester of hyaluronic acid (HA). In combination with mesenchymal stem cells (MSCs), Hyalofast supports the regeneration of hyaline-like cartilage.

Hyalofast has been used commercially to successfully treat more than *30,000 patients* in over *30 countries* over the last *14 years*.

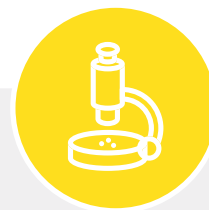

The Hyaff 3D scaffold has a dual role in tissue regeneration



Structural Role

Supports MSC adhesion and 3D organisation, facilitating recovery of the original tissue anatomy.



Biological Role

As the Hyaff fibres degrade, the polymer releases the parent molecule enriching the transplantation site with hyaluronic acid. This creates a HA-rich embryonic-like environment favourable to tissue regeneration.¹

Simple

Hyalofast in combination with MSCs supports the regeneration of durable hyaline-like cartilage in a single-step procedure. It's easily applied in mini-arthrotomy or in arthroscopy procedures.

- Uniform 3D structure: Can be applied on either side, folded and stacked if required.
- Good self-adherence, so fixation is not required in most cases
- Minimal additional instrumentation or device requirements

Adaptable

Hyalofast can be used with human mesenchymal stem cell (MSC), acting as a scaffold for MSCs or as a chondroprotective coverage after bone marrow stimulation procedures.

- Effective for chondral and osteochondral defects of the ankle and knee
- Easily adaptable to lesion shape and size
Can be used in large and small defects

Proven



Effective regeneration

Regenerated tissue type

Hyalofast results in hyaline-like cartilage regeneration, confirmed by T2 mapping².

Gold standard

Clinical and MRI results comparable to matrix-induced ACI (MACI)^{3,4}, which is viewed as the "gold standard" for treatment of large cartilage lesions.

Large patellofemoral lesions

Proven option for the treatment of challenging lesions^{3,5}, with results comparable to MACI.

OCD lesions

MRI showed satisfactory morphologic repair in deep osteochondral defects, with a concurrent reduction in symptoms, increase in function and stability of results at three-year follow-up⁶.



Clinically challenging patient population

Patients over 45 years of age

Effective even for large chondral defects in elderly patients, with outcomes comparable to younger patients⁷.



Durable clinical results

Results stable up to 10 years

Hyalofast provides good to excellent clinical outcomes at long-term follow-up in the repair of cartilage tissue (range: 6-10 years)⁸.

Hyalofast vs. microfracture alone

Hyalofast shows clinical results superior to microfracture alone, stable up to medium-term follow-up^{9,10}.

Indications

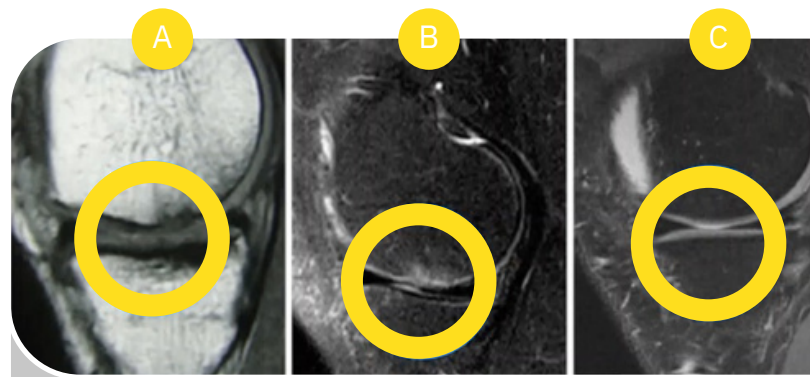
Hyalofast is CE-marked as a biodegradable support for the entrapment of mesenchymal stem cells for the repair of chondral and osteochondral lesions. It acts as a support for bone marrow aspirate or as a chondroprotective coverage, which favors in situ residence of mesenchymal stem cells after their mobilization due to microfracture or perforation procedures.

What kind of cartilage lesions?

ICRS Grade 3 and 4 single or multiple lesions caused by:

- Acute trauma
- Repeated microtrauma
- Instability and/or malalignment (in association with reconstructive and/or corrective surgery)
- Osteochondritis dissecans (OCD)

For complete product information including indications, contraindications, warnings, precautions, possible complications and product storage, please refer to the product IFU.



Treatment of patients over 45 years old⁷

- A:** Sagittal section of a MRI image of a Grade 4 cartilage lesion involving the articular surface of the medial femoral condyle
- B:** One-year follow-up MRI
- C:** Five-year follow-up MRI

144714F	Hyalofast® 2x2
144722F	Hyalofast® 5x5

References

1 Bauer C., Niculescu-Morzea E., Jeyakumar V., et al. Chondroprotective effect of high-molecular-weight hyaluronic acid on osteoarthritic chondrocytes in a co-cultivation inflammation model with M1 macrophage s. *J Inflamm (Lond)*. 2016 Sep 13;13(1). 2 Battaglia M., et al. Validity of T2 mapping in characterization of the regeneration tissue by bone marrow derived cell transplantation in osteochondral lesions of the ankle. *Eur J Radiol*. 2011 Nov;80(2):e132-9. Epub 2010 Aug 30. 3 Gobbi A., Chaurasia S., Karnatzikos G., et al. Matrix-induced autologous chondrocyte implantation versus multipotent stem cells for the treatment of large patellofemoral chondral lesions: a nonrandomized prospective trial. *Cartilage*. 2015;6(2):82-97. 4 Buda R., Vannini F., Castagnini F., et al. Regenerative treatment in osteochondral lesions of the talus: autologous chondrocyte implantation versus one-step bone marrow derived cells transplantation. *Int Orthop*. 2015 May;39(5):893-900. Epub 2015 Feb 8. 5 Buda R., et al. A useful combination for the treatment of patellofemoral chondral lesions: realignment procedure plus mesenchymal stem cell-retrospective analysis and clinical results at 48 months of follow-up. *Eur J Orthop Surg Traumatol*. 2019 Feb;29(2):461-470. Epub 2018 Sep 17. 6 Vannini F., et al. "One step" treatment of juvenile osteochondritis dissecans in the knee: clinical results and T2 mapping characterisation. *Orthop Clin North Am*. 2012;43(2):237-44. 7 Gobbi A., et al. One-step surgery with multipotent stem cells and Hyaluronan-based scaffold for the treatment of full-thickness chondral defects of the knee in patients older than 45 years. *Knee Surg Sports Traumatol Arthrosc*. 2017 Aug;25(8):2494-2501. Epub 2016 Jan 14. 8 Gobbi A., Whyte GP. Long-term clinical outcomes of one-stage cartilage repair in the knee with hyaluronic acid-based scaffold embedded with mesenchymal stem cells sourced from bone marrow aspirate concentrate. *Am J Sports Med*. 2019 Jun;47(7):1621-1628. Epub 2019 May 16. 9 Gobbi A., Whyte GP. One-stage cartilage repair using a hyaluronic acid-based scaffold with activated bone marrow-derived mesenchymal stem cells compared with microfracture: Five-year follow-up. *Am J Sports Med*. 2016 Nov;44(11):2846-2854. Epub 2016 Jul 29. 10 Tahta M., et al. Arthroscopic treatment of osteochondral lesions of the talus: nanofracture versus hyaluronic acid-based cell-free scaffold with concentration of autologous bone marrow aspirate. *J Orthop Surg*. 2017;25(2).

Speak to your local Business Development Manager, for further information using the details below:

T: 01443 719 555

E: customerservice@hospitalinnovations.co.uk

W: www.hospitalinnovations.com

Hospital Innovations Limited
Concept House
Talbot Green Business Park
Pontyclun
CF72 9FG